

Case report

Open Access

Liposarcoma of the tongue: case report and review of the literature

Marika R Dubin and Edward W Chang*

Address: Department of Otolaryngology – Head and Neck Surgery, Columbia University – New York Presbyterian Hospital, 180 Fort Washington Ave., HP 818, New York 10032, USA

Email: Marika R Dubin - md2148@columbia.edu; Edward W Chang* - ewc3@columbia.edu

* Corresponding author

Published: 26 July 2006

Received: 06 March 2006

Head & Face Medicine 2006, 2:21 doi:10.1186/1746-160X-2-21

Accepted: 26 July 2006

This article is available from: <http://www.head-face-med.com/content/2/1/21>

© 2006 Dubin and Chang; licensee BioMed Central Ltd.

This is an Open Access article distributed under the terms of the Creative Commons Attribution License (<http://creativecommons.org/licenses/by/2.0>), which permits unrestricted use, distribution, and reproduction in any medium, provided the original work is properly cited.

Abstract

Background: Liposarcoma most commonly arises in the retroperitoneum and lower extremities. Liposarcoma of the head and neck is rare, with only 12 previously reported cases of liposarcoma in the tongue.

Case presentation: We present a case of well-differentiated liposarcoma of the tongue occurring in a 39 year old man, treated with surgical excision. At 14 years of follow-up, the patient remains free of disease.

Conclusion: Liposarcoma of the head and neck is rare, and may easily be misdiagnosed clinically. The diagnosis is made histologically. Clinical behavior is related to histopathologic subtype. Wide surgical excision is the treatment of choice, with limited data to support the use of radiation or chemotherapy. Our case represents the longest follow-up period for a tongue liposarcoma, with 14 years disease-free following surgical extirpation.

Background

Liposarcoma is a malignant mesenchymal neoplasm that arises from adipose tissue, most commonly in the retroperitoneum and lower extremities. Liposarcoma of the head and neck is rare, representing 5.6% to 9% of cases in large series [1-3]. Common sites of occurrence in the head and neck region include the larynx, hypopharynx, oral cavity, orbit, scalp and soft tissues of the neck. In a recent review, Nikitakis et al [4] identified 44 cases of oral liposarcoma published in the English language literature between 1944 and 2001. Liposarcoma of the oral cavity demonstrates a predilection for the cheek [4-6], with other sites including the floor of the mouth, palate, gingiva, mandible, and tongue. To our knowledge, there have been only 12 previously reported cases of liposarcoma of the tongue in the English language literature (Table 1). We

present a case of well-differentiated liposarcoma of the tongue and review the current literature.

Case presentation

A 39 year old man presented in late 1990 to an outside institution with a right lateral tongue mass. His past medical history was significant only for alcohol abuse and a history of syphilis. His physical examination revealed a 1 × 1 cm mass on the right lateral aspect of the tongue (Figure 1). The mass was felt to be a traumatic lesion secondary to abrasion against a fractured tooth. The fractured tooth was extracted. Six months later, the mass continued to enlarge in size and the patient presented to our institution. Preliminary diagnosis was fibroma and an excisional biopsy was performed. The pathologic specimen measured 1.6 × 1.5 × 1.3 cm in size. Microscopic examination revealed a well-circumscribed tumor composed of varying

Table 1: Cases of liposarcoma of the tongue published in the English language literature

Authors	Age	Sex	Size	Histopathology	Follow-up
Larson et al (1976) (11)	42	F	1.5 × 1.5 cm	WD	No follow-up available
Wescott and Correll(1984) (12)	61	M	3.5 × 3 × 2 cm	Myxoid, WD	No follow-up available
Guest (1992) (13)	71	M	1 cm	Myxoid, WD	2 y, NED
Minic (1995) (6)	68	F	2.5 × 1.5 × 1 cm	Myxoid, WD	3 y, NED
Saddik et al (1996) (14)	76	M	2.5 cm	WD	No follow-up available
Nelson et al (1998) (15)	37	M	3 × 3 × 3 cm	WD	1.5 y, NED
Gagari et al (2000) (9)	73	M	2 × 1 × 1 cm	WD lipoma-like	No follow-up available
Orita et al (2000) (16)	70	M	1 × 3.5 cm	WD lipoma-like	8 mo, NED
Moore et al (2001) (17)	43	M	8 mm	WD/Atypical lipoma	10 mo, NED
Nunes et al (2001) (18)	65	M	1 cm	WD	No follow-up available
Bengezi et al (2002) (19)	67	M	1.5 × 2.5 cm	Myxoid	2 y, NED
Capodiferro et al (2004) (20)	58	F	2.5 × 1.5 cm	WD	2 y, NED
Present Case	39	M	1.6 × 1.5 × 1.3 cm	WD	14 y, NED

WD = well-differentiated, NED = no evidence of disease

sized fat cells, fibrous tissue and numerous blood vessels. Numerous lipoblasts were present, and nuclei throughout the tumor were pleomorphic and hyperchromatic. Mitotic figures were present but rare (Figures 2 and 3). A diagnosis of well-differentiated liposarcoma was made. The case was presented to Tumor Board at Columbia Presbyterian Medical Center and the recommendation was for wide local excision of the previously biopsied area. The patient was taken back to the operating room and 1 cm margins of the previously biopsied area were obtained with a KTP laser. Histologic inspection revealed no evidence of residual tumor. Fourteen years later, the patient remains free of disease. This is the longest follow-up of a tongue liposarcoma in the current literature.

Conclusion

Liposarcoma demonstrates a peak occurrence between the 4th and 6th decade, with a slight male preponderance [2,3,7,8]. It typically presents as a painless, slowly enlarg-

ing mass, only becoming symptomatic when impinging upon surrounding structures [6,9,10]. In the majority of previously described cases of liposarcoma of the tongue, the only presenting feature was a painless mass [6,9,11-15,18-20]; one patient complained of local irritation against the teeth [17] and another complained of saliva dribbling from the mouth [16].

Liposarcoma can easily be misdiagnosed clinically. Its relatively indolent course often results in a misdiagnosis of cyst or benign soft tissue neoplasm; it is frequently mistaken for lipoma [12]. Liposarcoma has been described as more firm, less easily compressed and more fixed to adjacent tissue than lipoma, and on gross inspection, as less yellow and less lobulated [12,21]. Nonetheless, many authors report difficulty in distinguishing these entities [21,22] and therefore histopathology is required for an appropriate diagnosis [12,19]. The histologic characteris-

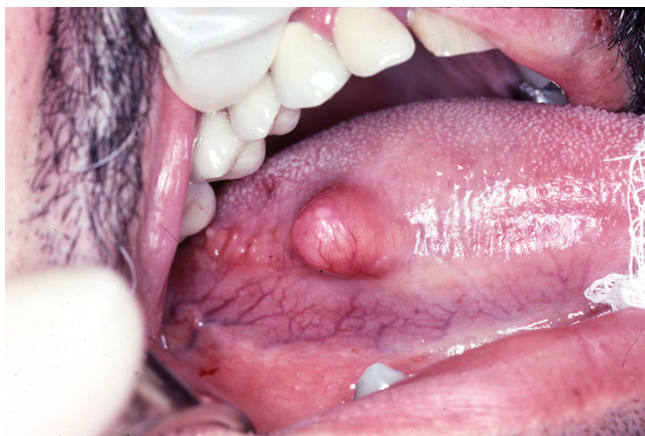

Figure 1
Gross appearance of the lesion on the right lateral aspect of the tongue.

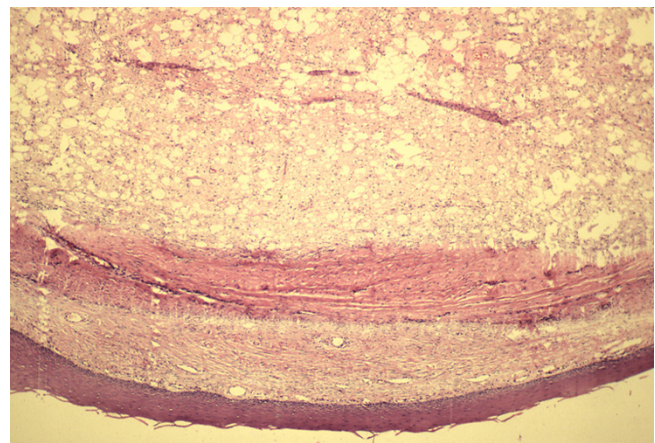


Figure 2
Low power view of well-differentiated liposarcoma demonstrating its well-circumscribed nature (hematoxylin-eosin, ×2.5).

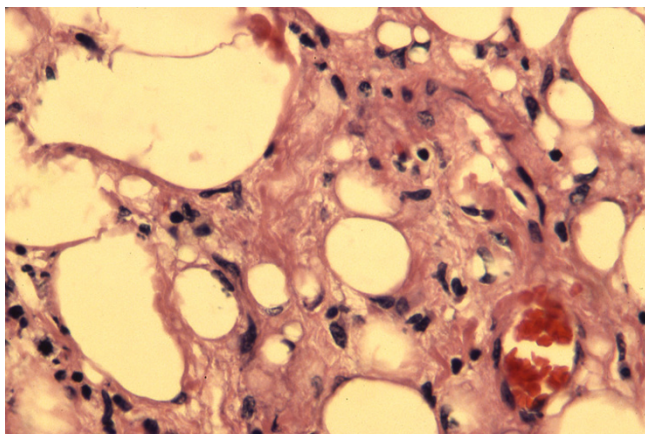


Figure 3
High power view demonstrating multiple lipoblasts in fibrous stroma. Note pleomorphic, hyperchromatic nuclei (hematoxylin-eosin, $\times 40$).

tics that distinguish liposarcoma from intramuscular lipoma include the presence of lipoblasts, cellular pleomorphism, vascular proliferation and mitotic activity [30].

Liposarcoma is characterized by a variety of histologic variants that have been the subject of an evolving process of classification. Currently, the World Health Organization distinguishes the four variants proposed by Enzinger and Weiss based on developmental stage of the lipoblasts and overall degree of cellularity and pleomorphism [1]. These four entities are described as well-differentiated, myxoid, round-cell and pleomorphic. The WHO also recognizes a fifth variant, dedifferentiated, to describe changes occurring within well-differentiated liposarcoma that correspond with more aggressive clinical behavior and poor outcome [17,24]. The well-differentiated type has been further subclassified into lipoma-like, inflammatory, and sclerosing types [9].

Enzinger and Winslow demonstrated that histologic type correlates with clinical behavior; similar findings have been made in subsequent reviews [23,25,26]. Patients with well-differentiated and myxoid type tumors have higher 5-year survival rates and lower recurrence rates than patients with pleomorphic and round-cell types. The incidence of metastasis is also correlated with histologic type. Round-cell and pleomorphic types have higher rates of metastasis than well-differentiated and myxoid types, which almost never metastasize [1,3,7,23,26].

Wide surgical excision is the treatment of choice for liposarcoma. Recurrence rate increases from 17% to 80% with incomplete excision [26], as may occur when tumors are mistakenly believed to be benign lipomas [5].

Although grossly these tumors appear to be encapsulated, they extend by infiltration; the likelihood of nearby satellite nodules necessitates wide excision [11,31]. Lymph node dissection is not indicated unless there is concrete evidence of metastasis, since the likelihood of nodal metastases in this disease is so rare [24].

Nonsurgical treatment modalities are of limited use in liposarcoma. The use of radiation therapy remains controversial. Pack and Pierson [8] reported an increase in 5-year survival from 50% to 87% with combined surgery and radiation therapy compared to surgery alone. Evans' [32] review of 55 cases demonstrated a decrease in local recurrence for patients with myxoid liposarcoma treated with surgery followed by radiation compared to surgery alone; however, a significant difference in survival between the two groups was not shown. McCulloch et al [26] reported 11 cases where radiation therapy was used, 9 of them in conjunction with surgery. Only 4 patients were disease free at the end of follow-up. Just as the benefit of radiation therapy remains to be proven, there has been little data with regard to the usefulness of chemotherapy in treatment of liposarcoma.

Prognosis of liposarcoma is influenced by three factors: histologic variant, adequacy of surgical excision, and location of the tumor [9]. Golledge et al [27] found a relatively favorable prognosis for liposarcoma of the scalp, face and larynx as compared with the oral cavity, pharynx and neck, and attributed this difference to earlier recognition of tumor. Several authors have noted deep-seated liposarcoma of the head and neck to be associated with higher rates of recurrence, likely owing to incomplete excision secondary to cosmetic and physiologic considerations [9,10,14]. The differential clinical behavior of tumors by site has led some authors to propose that well-differentiated tumors in superficial locations be classified as "atypical lipomas"; these tumors, while histologically similar to the well-differentiated type, are notable for their comparative ease of resection and decreased morbidity [22,29].

The role of tumor size in prognosis is unclear. Golledge et al [27] noted in their study of 76 patients that tumor size did not affect prognosis, however some authors have identified small size with better survival rate [3] and less risk of recurrence [28]. Several authors have commented that the prognosis of liposarcoma of the oral cavity is generally favorable because of the predominance of myxoid and well-differentiated types and the small size of these neoplasms. [6,16].

In summary, liposarcoma of the head and neck is rare, with only a handful of cases reported in the tongue. Liposarcoma of the tongue typically presents as a slow-growing painless mass, and may easily be mistaken for

benign lipoma. Diagnosis is made histologically. The histopathologic variant influences clinical behavior and prognosis, with well-differentiated and myxoid tumors following a more benign course. The treatment of choice is wide surgical excision. The benefit of radiation and chemotherapy remains unproven. We present a case of a tongue liposarcoma with only surgical extirpation, and with a 14 year follow-up free of disease.

Abbreviations

N/A

Competing interests

The author(s) declare that they have no competing interests.

Authors' contributions

EWC treated the patient and provided follow-up. MRD researched the current literature. MRD and EWC co-wrote the contents of this manuscript.

Acknowledgements

No sources of funding contributed to the development of this manuscript.

References

1. Enzinger FM, Weiss SW: **Liposarcoma**. In *Soft tissue tumours* 2nd edition. St. Louis, MO: Mosby-Year Book; 1988:346-382.
2. Stout AP: **Liposarcoma: the malignant tumor of lipoblasts**. *Ann Surg* 1944, **119**:86-107.
3. Enterline HT, Culbertson JD, Rochlin DB, Brady LW: **Liposarcoma: a clinical and pathological study of 53 cases**. *Cancer* 1960, **13**:932-950.
4. Nikitakis NG, Lopez MA, Pazoki AE, Ord RA, Sauk JJ: **MDM2+/CDK4+/p53+ oral liposarcoma: a case report and review of the literature**. *Oral Surg Oral Med Oral Pathol Oral Radiol Endod* 2001, **92**:194-201.
5. Fusetti M, Silvagni L, Eibenstein A, Chiti-Batelli S, Hueck S, Fusetti M: **Myxoid liposarcoma of the oral cavity: Case report and review of the literature**. *Acta Otolaryngol* 2001, **121**:759-762.
6. Minic AJ: **Liposarcomas of the oral tissues: a clinicopathologic study of four tumors**. *J Oral Pathol Med* 1995, **24**:180-184.
7. Enzinger FM, Winslow DJ: **Liposarcoma: a study of 103 cases**. *Virchows Arch* 1962, **335**:367-388.
8. Pack GT, Pierson JC: **Liposarcoma: a study of 105 cases**. *Surgery* 1954, **36**:686-712.
9. Gagari E, Kabani S, Gallagher GT: **Intraoral liposarcoma: Case report and review of the literature**. *Oral Surg Oral Med Oral Pathol Oral Radiol Endod* 2000, **89**:66-72.
10. Zheng J, Wang Y: **Liposarcoma of the oral and maxillofacial region: an analysis of 10 consecutive patients**. *J Oral Maxillofac Surg* 1994, **52**:595-598.
11. Larson DL, Cohn AM, Estrada RG: **Liposarcoma of the tongue**. *J Otolaryngol* 1976, **5**:411-414.
12. Wescott WB, Correll RW: **Multiple recurrences of a lesion at the base of the tongue**. *J Am Dent Assoc* 1984, **108**:231-232.
13. Guest PG: **Liposarcoma of the tongue: a case report and review of the literature**. *Br J Oral Maxillofac Surg* 1992, **30**:268-269.
14. Saddik M, Oldring DJ, Mourad WA: **Liposarcoma of the base of tongue and tonsillar fossa. A possibly underdiagnosed neoplasm**. *Arch Pathol Lab Med* 1996, **120**:292-295.
15. Nelson W, Chuprevich T, Galbraith DA: **Enlarging tongue mass**. *J Oral Maxillofac Surg* 1998, **56**:224-227.
16. Orita Y, Nishizaki K, Ogawra T, et al: **Liposarcoma of the tongue: case report and literature update**. *Ann Otol Rhinol Laryngol* 2000, **109**:683-686.
17. Moore PL, Goede A, Phillips DE, Carr R: **Atypical lipoma of the tongue**. *J Laryngol Otol* 2001, **115**:859-861.
18. Nunes FD, Loduca SVL, de Oliveira EMF, de Araujo VC: **Well-differentiated liposarcoma of the tongue**. *Oral Oncol* 2002, **38**:117-119.
19. Bengezi OA, Kearns R, Shuhaibar H, Archibald SD: **Myxoid liposarcoma of the tongue**. *J Otolaryngol* 2002, **31**:327-328.
20. Capodiferro S, Scully C, Maiorano E, Lo Muzio L, Favia G: **Liposarcoma circumscriptum (lipoma-like) of the tongue: report of a case**. *Oral Dis* 2004, **10**:398-400.
21. Hajdu SI: **Tumors of Adipose Tissue**. In *Pathology of Soft Tissue Tumors* Philadelphia: Lea & Febiger; 1979:227-295.
22. Evans HL, Soule EH, Winkelmann RK: **Atypical lipoma, atypical intramuscular lipoma and well-differentiated retroperitoneal liposarcoma**. *Cancer* 1979, **43**:574-584.
23. Enzinger FM, Winslow DJ: **Liposarcoma: a study of 103 cases**. *Virchows Arch Pathol Anat Histopathol* 1962, **355**:367-388.
24. Newlands SD, Divi V, Stewart CM: **Mixed myxoid/round cell liposarcoma of the scalp**. *Am J Otolaryngol* 2003, **24**:121-127.
25. Tanaka M, Hizawa K, Tonai M: **Liposarcoma: a clinicopathological study on 136 cases based on the histologic subtyping of WHO**. *Jpn J Cancer Clin* 1974, **20**:1036-1047.
26. McCulloch TM, Makielski KH, McNutt MA: **Head and neck liposarcoma**. *Arch Otolaryngol Head Neck Surg* 1992, **118**:1045-1049.
27. Golledge J, Fisher C, Rhys-Evans PH: **Head and neck liposarcoma**. *Cancer* 1995, **76**:1051-1058.
28. Fanburg-Smith JC, Furlong MA, Childers ELB: **Liposarcoma of the oral and salivary gland region: a clinicopathologic study of 18 cases with emphasis on specific sites, morphologic subtypes, and clinical outcome**. *Mod Pathol* 2002, **15**:1020-1031.
29. Stewart MG, Schwartz MR, Alford BR: **Atypical and malignant lipomatous lesions of the head and neck**. *Arch Otolaryngol Head Neck Surg* 1994, **120**:1151-1155.
30. Garavaglia J, Gnepp DR: **Intramuscular (infiltrating) lipoma of the tongue**. *Oral Surg Oral Med Oral Pathol* 1987, **63**:348-350.
31. Collins BT, Gossner G, Martin DS, Boyd JH: **Fine needle aspiration biopsy of a well-differentiated liposarcoma of the neck in a young female**. *Acta Cytol* 1999, **43**:452-456.
32. Evans HL: **Liposarcoma: a study of 55 cases with a reassessment of its classification**. *Am J Surg Pathol* 1979, **3**:507-522.

Publish with **BioMed Central** and every scientist can read your work free of charge

"BioMed Central will be the most significant development for disseminating the results of biomedical research in our lifetime."

Sir Paul Nurse, Cancer Research UK

Your research papers will be:

- available free of charge to the entire biomedical community
- peer reviewed and published immediately upon acceptance
- cited in PubMed and archived on PubMed Central
- yours — you keep the copyright

Submit your manuscript here:
http://www.biomedcentral.com/info/publishing_adv.asp

